International Journal of Medical and Health Sciences

Journal Home Page: http://www.ijmhs.net ISSN:2277-4505

Case Report

A rare incidental dual malignancy in Ectopic and Orthotopic Thyroids

L.Krishna[1*], B.Vijayanirmala[2], K. Ramadevi [3], N.L.N. Moorthy[4], O.Shravan Kumar[5]

[1]Professor, [2&3]Assistant Professors, [5]Professor &HOD Department of Pathology, Gandhi Medical College, Secunderabad,

[4]Professor &HOD Department of Radiology, Gandhi Medical College, Secunderabad.

ABSTRACT

Ectopic thyroid tissue may be encountered anywhere from the foramen caecum to the lower neck. It is rarely seen in the mediastinum. True malignant transformation in ectopic thyroid tissue is rare. Cases of ectopic primary thyroid carcinoma with another primary malignancy in the orthotopic thyroid is extremely rare. We report on an extremely rare case of true mediastinal primary thyroid carcinoma with another malignancy in the orthotopic thyroid suggesting a de novo process in a 45 year old female. The clinicopathologic features and diagnosis of the lesion with regard to its mediastinal location are discussed.

KEYWORDS: Dual malignancy, Ectopic thyroid, papillary carcinoma, hurthle cell carcinoma, Orthotopic thyroid.

INTRODUCTION

Heterotopic thyroid tissue can be found not only as a component of thyroglossal duct cyst but anywhere along the course of the thyroglossal duct cyst, sometimes as the sole abnormality. The most frequent location is the base of the tongue. At a microscopic level lingual thyroid is found in 10% of normal individuals [1]. Other sites of ectopic thyroid tissue are the anterior tongue, submandibular region, larynx, trachea, mediastinum usually superior and heart. Heterotopic thyroid tissue in any of these locations is subject to the same diseases that can affect the main gland, including inflammation, hyperplasia and tumors. Thus several cases of follicular carcinoma arising from lingual thyroid have been reported [2].

CASE REPORT

A 45 Year old female patient was admitted to the hospital for incisional hernia repair. During her surgical work up incidentally she was found to have mediastinal mass on chest x-ray. On physical examination, thyroid was normal and no lymph node was palpable in the neck. Ultrasound examination showed enlarged left lobe of thyroid CT neck and chest showed well defined enhancing SOL in anterior mediastinum of 8 x 6 cm extending in to left paratracheal region with specs of calcification. [Figure1].

CT neck showed enlarged left lobe thyroid that appears continuous with above mass. Radioactive iodine scintigraphy revealed cold nodule in left lobe of thyroid. No iodine uptake for mediastinal mass. No association of mass with thyroid is established. The patient was subjected to median sternotomy for excision of anterior mediastinal mass. Intraoperative evaluation of mediastinal mass showed no glandular continuity between the thyroid gland and the mass. Grossly mediastinal mass is measuring 10X8X3 cm. Cut section shows encapsulated tumor measuring 6X5 cm, grey white to grey brown in color. [Figure 2].Microscopically sections show normal thyroid tissue along with tumor tissue arranged in papillary pattern. Individual cells show vesicular nuclei with ground glass appearance. A diagnosis of papillary carcinoma was made. [Figure3]

Totalorthotopic thyroidectomy was done one month after mediastinal mass resection. Totalthyroidectomy specimen is measuring 7X3x1cm with nodular surface. Cut section shows 2.5X2 cm grey brown nodule. Sections show a tumor tissue composed of hurthle cells arranged in nesting pattern, as solid sheets and occasional follicular pattern. The tumor tissue is seen infiltrating into the surrounding normal thyroid in focal areas. [Figure 4]. A diagnosis of hurthle cell carcinoma was made. The post-operative period is uneventful. The patient is asymptomatic and disease free sixteen months after surgery.

Figure :1 Contrast enhanced CT scan Chest shows homogeneously enhancing superior mediastinal mass 8.4 x5.4 cm with specs of calcification in the periphery



Figure :2 Mediastinal Thyroid with tumor-gross appearnace

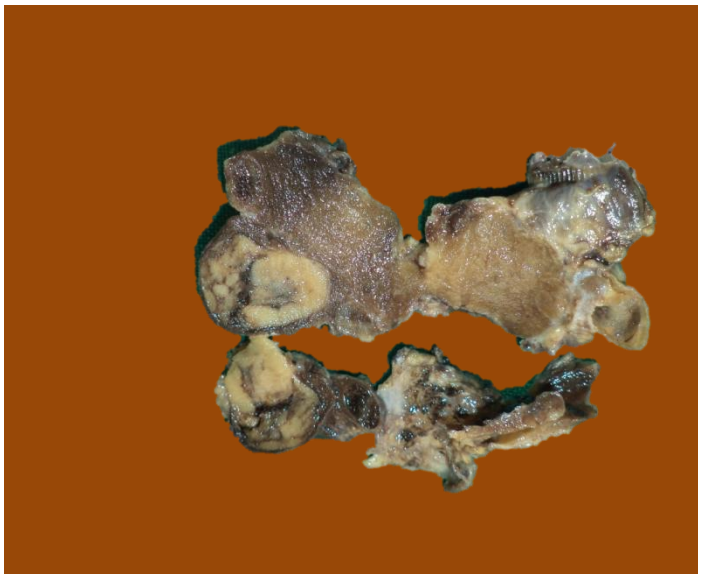

Figure :3 Papillary carcinoma of thyroid - mediastinal mass.[H&E 40 X]

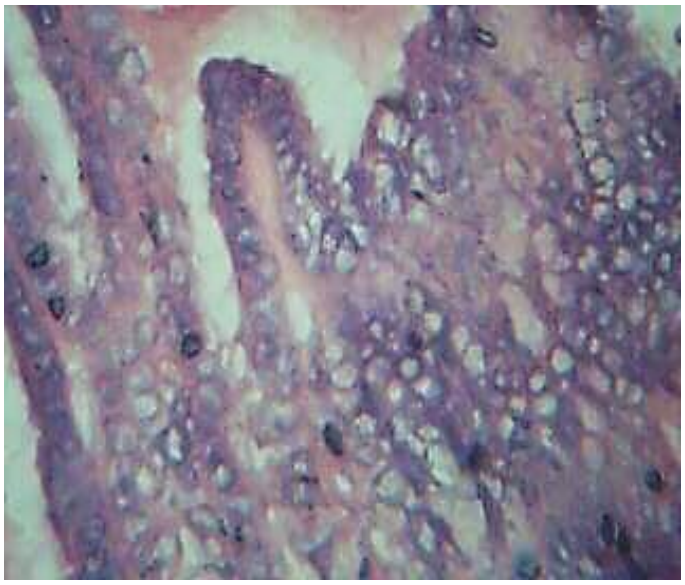

Figure :4 Hurthle cell carcinoma - orthotopic thyroid [H&E 10 X] Section with infiltration into normal thyroid.

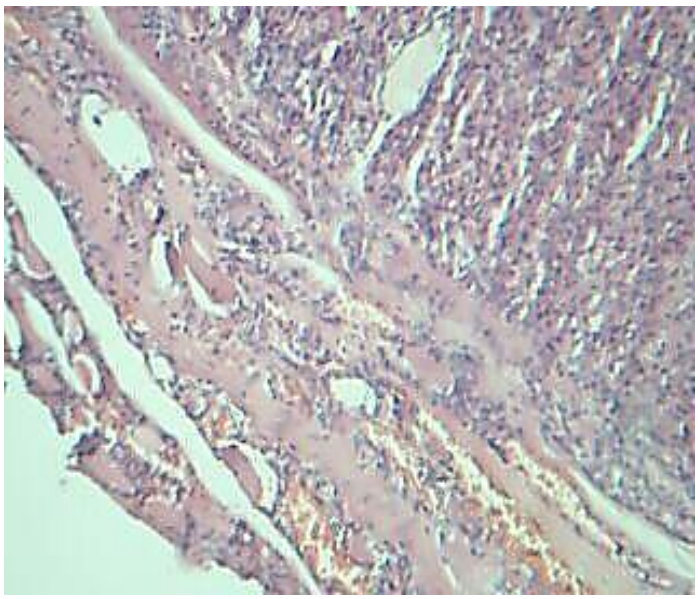

DISCUSSION

Historically there have been two distinct categories of aberrant or ectopic thyroid tissue, one is lateral in its location and the other is in the midline. Median ectopic thyroid may be encountered from the tongue to the diaphragm. The development and descent of the thyroid is in anatomical juxtaposition with the heart, which lies just inferior to the tuberculumimpar in the embryo. The mechanical effects of the descending heart on the thyroid gland contribute significantly to the development of the various anomalies of thyroid position anywhere from the foramen caecum to the diaphragm. Lingual thyroid is the most common type accounting for 90% of cases. The sublingual types may be suprahyoid, infrahyoid or at the level of the hyoid bone[3].

In 1869, Hickman reported the first case of ectopic thyroid tumor of the base of the tongue, pressing down the epiglottis on the larynx and causing death by suffocation sixteen hours

after birth[4]. The Ectopic thyroid may lie in the mediastinum, larynx, trachea and esophagus[5]. The presence of ectopic thyroid tissue in other places distant from the neck region include the heart, ascending aorta, thymus, oesophagus, duodenum, gall bladder [6], stomach bed, pancreas, mesentery of the small intestine, porta hepatis, adrenal gland, ovary, fallopian tube, uterus, and vagina[7].

Genetic research has been shown that the gene transcription factors TITF-1(NKx2-1), Foxe 1 (TITF-2) and PAX-8 are essential for thyroid morphogenesis and differentiation. Mutation in these Genes may be involved in abnormal migration of the thyroid[8, 9]. Primary thyroid carcinomas arising from ectopic thyroid tissue are uncommon and have been reported to arise from thyroid tissue in the thyroglossal cysts, lateral aberrant thyroid tissue, lingual thyroid, mediastinal, andStrumaovarii. Most tumors in the ectopic locations have been papillary carcinomas, mixed follicular and papillary carcinomas or hurthle cell tumors [10].

Patients with intrathoracic goiter are usually asymptomatic with the tumor reported as an incidental finding on chest roentgenogram[11], Similar to our case. Mediastinal ectopic thyroid carcinoma is extremely rare as most cases do not meet the criteria of ectopic thyroid tissue. Our case is a true ectopic mediastinal thyroid as it met the criteria of ectopic thyroids i.e. Intraoperative evaluation of mediastinal mass showed no glandular continuity between the thyroid gland and the mass. The cervical thyroid gland does not have a similar pathologic process as the ectopic tumor[12].

Surgical excision is the mainstay of treatment as these tumors usually give rise to compressive symptoms. Thoracotomy or sternotomy is usually required for mediastinal thyroid tumors. The primary treatment after mediastinal mass resection is total thyroidectomy. Complete thyroid resection, not only excludes the thyroid gland as the primary source of malignancy but also facilitates future patient management by serum thyroglobulin measurement and whole body iodine scintigraphy.

CONCLUSION

Mediastinal ectopic thyroid carcinoma is extremely rare. Synchronous presentation of carcinomas of two different histologic variants as primary malignancies in orthotopic and ectopic thyroids have not been reported in literature till date.

REFERENCES

1. Sauk JJ Jr.Ectopic lingual thyroid. J pathol 1970, 102; 239-243.

2. Diaz-Arias AA, Bickel JT, Loy TS, Croll GH, Puckett CL, Havey AD.Follicular Carcinoma with clear cell change arising in lingual thyroid. Oral Surg Oral Med Oral Pathol. 1992, 74: 206-211.

3. Batsakis JG, El-Naggar AK, Luna MA.Thyroid gland ectopias. Am J OtoRhinoLaryngol1996; 105: 996-1000.

4. Hickman W.Congenital tumor of the base of the tongue, pressing down the epiglottis on the larynx and causing death by suffocation sixteen hours after birth. Trans PatholSocLond 1869;20: 160-161.

5. FishJ, Moore RM. Ectopic thyroid tissue and ectopic thyroid carcinoma: a review of the literature and report of a case. AnnSurg 1963; 157:212-21

6. Liang K, Liu JF, Wang YH, Tang GC, Teng LH, Li F, Ectopic thyroid presenting as a gallbladder mass. Ann R CollSurgEngl 2010; 92: W4-6.

7. Kurman RJ, Prabha AC, Thyroid and parathyroid 268 N.A. Ibrahim, I.O. Fadeyibi glands in the vaginal wall: report of a case. Am J ClinPathol. 1973; 59: 503-507.

8. Felice MD, Lauro RD, Thyroid Development and its disorders: Genetic and molecular mechanisms. Endocrine Reviews 2004; 25: 722-746.

9. Gillam MP, Kopp P, Genetic regulation of thyroid development. CurrOpinPediatr2001; 13: 358–363.

10. Mishriki Y Y, Lane BP, Lozowski MS, Epstein H. Hurthle cell tumor arising in the mediastinal ectopic thyroid and diagnosed by fine needle aspiration: light microscopic and ultra-structural features.Actacytol 1983; 27:188-92.

11.GrondinS.C, Buenaventura P, LuketichJD.Thoracoscopic resection of an ectopic intrathoracic goiter. Ann Thoracsurg 2001; 71:1697-8

12. Sean C Grondin, Percival Beunaventura, James D Luketich.The Annals of Thoracic Surgery 2001; 71:1697-1698.

*Corresponding author: Dr L. Krishna
E-Mail: lanka.krishna1@gmail.com